WHITEPAPER

IHC Applications:
Paget's Disease of the Breast

BIOCARE
MEDICAL

IHC Applications: Paget's Disease of the Breast

Mammary Paget's Disease (MPD) is a rare and often misdiagnosed type of breast cancer that primarily affects the nipple and areola complex.[2,7] It occurs in approximately 1- 4% of all breast cancer cases and typically presents with eczema-like changes, such as redness, itching, and scaling of the nipple and areola.[2,7] Most patients with MPD have one or more tumors inside the same breast, either breast carcinoma in situ or invasive breast carcinoma.[2,4,7] While IHC may not be the sole diagnostic tool for MPD, it may play a crucial role in confirming the disease and guiding treatment decisions.

The characteristic histopathological feature of MPD is the presence of malignant Paget cells within the epidermis of the nipple and areola.[1,2] These cells have pale, mucin-containing cytoplasm, irregularly sized nuclei, and prominent nucleoli.[1,6] IHC markers such as Cytokeratin 7 (CK7), GATA3, and HER2 may be used to highlight Paget cells.[1,5] These stains may help pathologists confirm the presence of MPD and differentiate it from benign conditions that can mimic its clinical presentation.[1]

Paget cells can be either of mammary or extramammary origin.[3] Mammary Paget's Disease arises from an underlying breast carcinoma, whereas extramammary Paget's Disease can originate from various internal organs.[3] IHC staining for markers such as androgen receptor (AR), estrogen receptor (ER), progesterone receptor (PR), human epidermal growth factor receptor 2 (HER2/neu), PDL-1, and GATA3 may help determine the mammary origin of Paget cells.[1,3,5] Knowing the hormone receptor status may also be crucial for determining treatment options. [1,3,5]

Paget's Disease of the Breast Illustrations

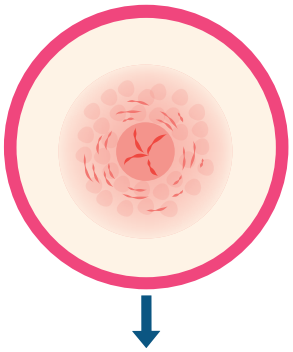

Redness, scaling and flaking of nipple

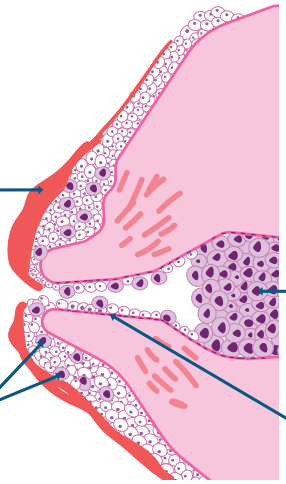

To learn more about the markers listed above, please visit our website at biocare.net or call 1-800-799-9499, option #3

1. Arain, S. A., Arafah, M., Said Raddaoui, E. M., Tulba, A., Alkhawaja, F. H., & Al Shedoukhy, A. (2020). Immunohistochemistry of mammary Paget's disease. Cytokeratin 7, GATA3, and HER2 are sensitive markers. Saudi medical journal, 41(3), 232–237. https://doi.org/10.15537/smj.2020.3.24949
2. Chen, C. Y., Sun, L. M., & Anderson, B. O. (2006). Paget disease of the breast: changing patterns of incidence, clinical presentation, and treatment in the U.S. Cancer, 107(7), 1448–1458. https://doi.org/10.1002/cncr.22137
3. Gatalica, Z, Vranic, S, Krušlin, B, et al. Comparison of the biomarkers for targeted therapies in primary extra-mammary and mammary Paget's disease. Cancer Med. 2020; 9: 1441–1450. https://doi.org/10.1002/cam4.2820
4. Harris JR, Lippman ME, Morrow M, Osborne CK, editors. Diseases of the Breast. 4th ed. Philadelphia: Lippincott Williams & Wilkins; 2009.
5. Liegl, B., Horn, LC. & Moinfar, F. Androgen receptors are frequently expressed in mammary and extramammary Paget's disease. Mod Pathol 18, 1283–1288 (2005). https://doi.org/10.1038/modpathol.3800437
6. Lloyd J, Flanagan AM, Mammary and extramammary Paget's disease Journal of Clinical Pathology 2000;53:742-749.
7. US Department of Health and Human Services National Institutes of Health. (2012, April 10). Paget Disease of the Breast. National Cancer Institute. https://www.cancer.gov/types/breast/paget-breast-fact-sheet