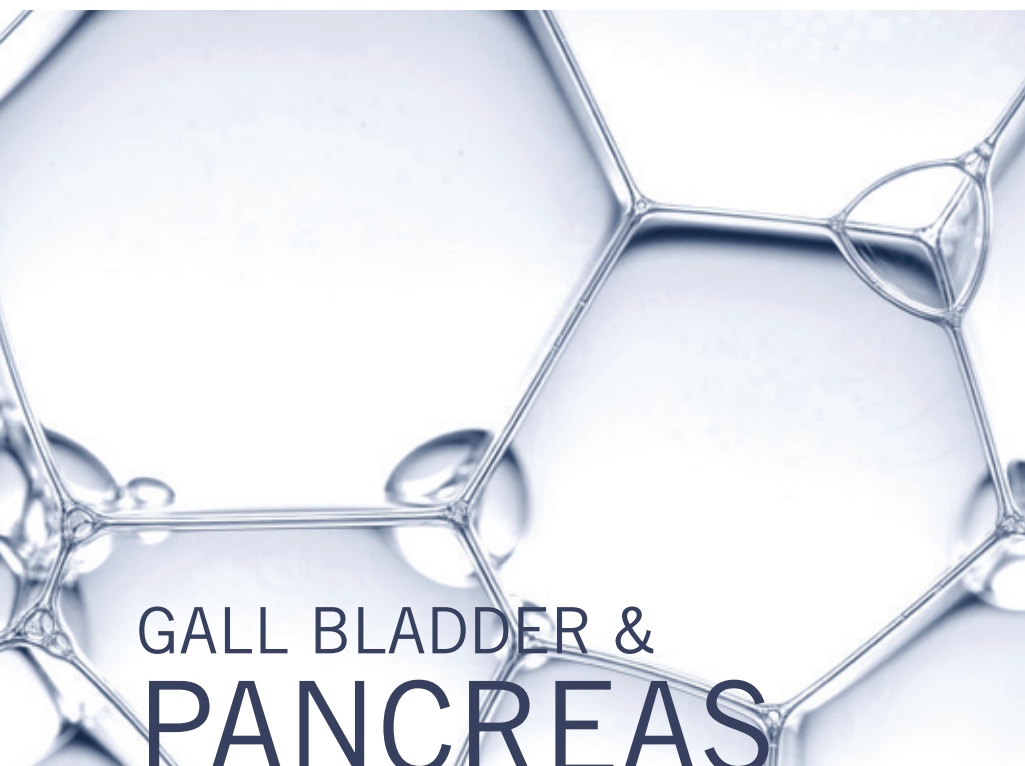


Key Antibodies For










Gall Bladder & Pancreatic Cancer



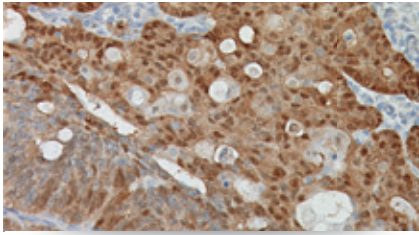
Pancreatic cancers are a rare diagnosed cancer in the United States, with about 3.0% of new cancer cases classified as pancreatic, contributing approx. 6.9% of cancer deaths yearly. As of 2012, there were approximately 46,000 people living with pancreatic cancer in the United States. Those diagnosed with pancreatic cancer have a 5 year survival rate of 7.2%. Over the last 10 years, the rate of new cancer cases has risen 0.8% while the death rate has risen 0.4% each year. Biocare Medical is proud to offer key pancreatic and gall bladder antibodies that may aid in the identification of their respective proteins by IHC in FFPE tissues.

SEER Cancer Statistics Factsheets: Pancreas Cancer. National Cancer Institute. Bethesda, MD, <http://seer.cancer.gov/statfacts/html/pancreas.html>

Key Antibodies for Gall Bladder & Pancreatic Cancer

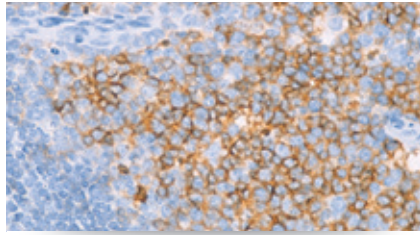
Product Name	Source	Clone	Catalog Number
β-Catenin		14	CM 406; PM 406
CD10		56C6	CM 129; PM 129; IP 129; OAI 129
Chromogranin A		LK2H10 + PHE5	CM 010; PM 010; IP 010; OAI 010
Cytokeratin 7 (CK7)		OV-TL 12/30	CM 061; PM 061; IPI 061; OAI 061
Cytokeratin 19 (CK19)		Ks19.1	CM 242; PM 242; OAI 242
E-cadherin (RM)		EP6	ACI 3012; API 3012
Glypican 3		1G12	CM 396; PM 396
Mucin 5AC (Gastric Mucin)		45M1	CM 231
S100P		Polyclonal	ACI 3010; ACI 3010

Key Antibodies for Gall Bladder & Pancreatic Cancer



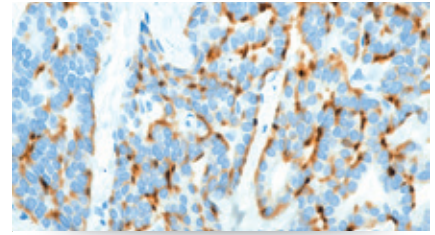
β-Catenin

β-Catenin stains the nucleus of more than 90% of solid pseudopapillary tumors and a large percentage of acinar cell carcinomas and pancreatoblastomas. Use with CD10, E-cadherin, and Chromogranin A for confirming a diagnosis of solid pseudopapillary tumors.



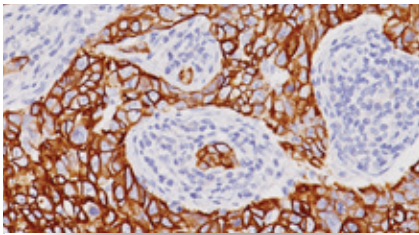
CD10

CD10 is positive in pancreatic neuroendocrine tumors and almost all solid pseudopapillary tumors. Negativity is seen in pancreatic ductal adenocarcinomas. Clear cell renal cell carcinoma metastasized to the pancreas is often positive for CD10.



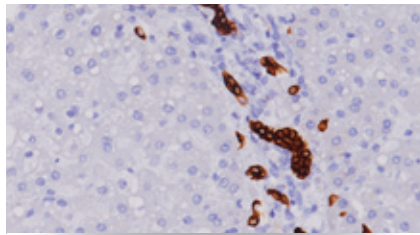
Chromogranin A

Chromogranin A is present in neuroendocrine cells throughout the body. Almost 100% of pancreatic neuroendocrine tumors are positive for Chromogranin. It is negative in pancreatic ductal adenocarcinomas, solid pseudopapillary tumors and serous cystadenoma.



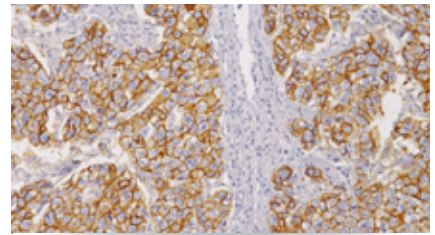
Cytokeratin 7 (CK7)

In acinar cell carcinoma of the pancreas, Cytokeratin 7 (CK7) is frequently negative or only focally positive. In pancreatic ductal carcinomas, CK7 is typically diffusely positive, providing an aid in differentiating these cancers. Pancreatic neuroendocrine tumors are frequently negative.



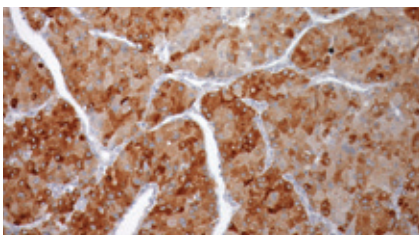
Cytokeratin 19 (CK19)

Cytokeratin 19 (CK19) is expressed in a high percentage of pancreatic ductal adenocarcinomas. Positivity in pancreatic neuroendocrine tumors may be associated with a more aggressive tumor type. CK19 is also often expressed in the squamous component of pancreatoblastomas.



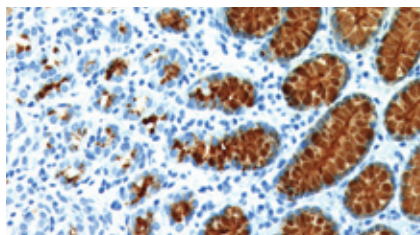
E-cadherin

E-cadherin expression is seen in pancreatic ductal adenocarcinomas, acinar cell carcinomas and pancreatic neuroendocrine tumors but is negative in solid pseudopapillary tumors. Use with Chromogranin A, CD10 and β-catenin as a confirmatory diagnosis.



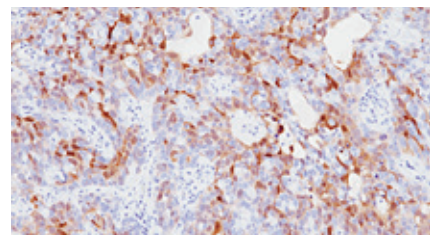
Glypican 3

Glypican 3 is an established marker for hepatocellular carcinoma and yolk sac tumor. It also shows positivity in a majority of acinar cell carcinoma of the pancreas but negative in pancreatic ductal adenocarcinomas, pancreatic neuroendocrine tumors and solid pseudopapillary tumors.



Mucin 5AC

Mucin 5AC (MUC5AC) has an important role in pancreatic tumorigenesis. Overexpression has been reported in 60% to 100% of pancreatic ductal adenocarcinomas. MUC5AC high expression has also been seen in cholangiocarcinoma and in gallbladder adenocarcinomas.



S100P

Expression of S100P has been reported in more than 90% of pancreatic ductal adenocarcinomas, and in gallbladder and extrahepatic adenocarcinomas. S100P expression is typically present in all types of intraductal papillary mucinous neoplasms. It is usually negative in acinar cell carcinomas.